

# Functional Rhinoplasty

David W. Kim, MD<sup>a,b,\*</sup>, Krista Rodriguez-Bruno, MD<sup>a</sup>

## KEYWORDS

- Functional rhinoplasty • Internal nasal valve
- External nasal valve • Upper lateral cartilages
- Lower lateral cartilages

Over the past couple of decades, there has been an increasingly sophisticated understanding of the pathophysiology underlying fixed nasal obstruction. In the past, submucous resection of the quadrangular cartilage, septoplasty, and inferior turbinate reduction procedures were the predominant work-horse techniques to address fixed nasal obstruction. Although these procedures continue to be a vital part of nasal airway surgery, they do not directly address other types of anatomic obstruction, such as insufficiency of the lateral nasal wall, pinching of the upper lateral cartilage (ULC), or alar collapse. Problems in these areas are part of the large group of disorders lumped into the term “nasal valve insufficiency.” To treat these problems, surgeons have adopted a greater range of operative techniques. Taken together, various combinations of these procedures are often described as “functional rhinoplasty.” Of note, the methods used within a functional rhinoplasty procedure may vary considerably among different surgeons.

This article reviews the common surgical maneuvers used to treat the various types of fixed nasal obstruction. By way of introduction, the anatomy, pathophysiology, and assessment of the anatomically obstructed nose are reviewed. Outcomes and efficacy of traditional nasal airway procedures are then discussed. Next, surgical techniques, nuances, and pitfalls for the treatment of the internal nasal valve area are detailed. Finally, alternative techniques used to treat the nasal valve areas are briefly reviewed.

## BACKGROUND AND SIGNIFICANCE

Functional and aesthetic rhinoplasties are intimately related. This has become even more

evident in the last 20 years, during which the field of facial plastic surgery has experienced an evolution in its surgical philosophy. Previously, emphasis had been placed on reductive techniques that achieved short-term, cosmetic goals, often used at the expense of nasal framework stability. With expanded understanding of the structural and dynamic roles of the nasal scaffold, an increased appreciation has developed for the consequences that surgical modifications have on dynamic nasal airflow.<sup>1,2</sup> Toriumi and coworkers<sup>3</sup> exemplified this trend and focused on a conservative surgical approach aimed at stabilizing and reorienting the nasal anatomic structures instead of reducing them, to ensure long-term cosmetic results while respecting and optimizing nasal airway function.

Functional and aesthetic complaints frequently overlap and the facial plastic surgeon is in a unique position optimally to address both. One of the most common patient grievances seen in many otolaryngology practices is nasal obstruction. Despite the frequency of such a problem, the task of identifying the nasal structures that contribute to the obstruction is not always straightforward.<sup>4</sup> Nasal septal abnormalities are often identified during physical examination, with an estimated 75% to 80% of adults exhibiting some degree of septal deviation.<sup>5</sup> This can mislead physicians who may focus their attention on this finding when planning their surgical approach. Some cases are clear-cut with prominent septal convexities that can be easily targeted surgically. In these patients, a septoplasty may be performed, which in several studies has been shown to be effective.<sup>6–9</sup> Recently, Stewart and colleagues<sup>6</sup> showed that patients with at least moderate septal deviation on examination reported a significant

<sup>a</sup> Department of Otolaryngology, Head and Neck Surgery, University of California, San Francisco, CA, USA

<sup>b</sup> Division of Facial Plastic and Reconstructive Surgery, University of California, San Francisco, CA, USA

\* Corresponding author. University of California, Box 1809, 2330 Post Street, San Francisco, CA 94143–1809. E-mail address: dkim@ohns.ucsf.edu (D.W. Kim).

improvement in nasal obstruction after septoplasty surgery, which persisted at 6 months. In a systematic review of the literature, Singh and colleagues<sup>10</sup> found septoplasty to benefit approximately 75% of patients with nasal obstruction.

Many patients exhibit a lesser degree of nasal septal deviation, however, and yet continue to have severe obstructive nasal symptoms. Most typically, this happens as a result of the nasal valves contributing to the obstruction, a process that only is evident during dynamic nasal inspiration. The internal valve is defined as the area between the caudal end of the ULC and the cartilaginous septum including the circumferential neighboring structures in the nasal airway. Narrowing at this location can cause difficulty with air flow. External valve insufficiency is caused by narrowing or weakness of the vestibular nasal wall, which collapses during inspiration.<sup>11</sup>

It is of key importance to perform a thorough preoperative evaluation given that nasal valve problems are often overlooked and the focus is placed only on the contributions from septal deviation and inferior turbinate hypertrophy. Inappropriate preoperative patient selection is closely associated with a patient's postoperative dissatisfaction.<sup>4,5</sup> Septoplasty has been shown to be effective for patients with obvious septal deviation. Long-term outcomes of septoplasty have been less successful for all categories of patients, however, when grouped together.<sup>12</sup> Jessen and colleagues<sup>13</sup> and Ho and colleagues<sup>14</sup> described redevelopment of nasal obstruction after septoplasty alone in as high as 50% of patients.

### **Outcomes Studies of Functional Rhinoplasty**

With the limitations of traditional septal and inferior turbinate surgery, surgeons have increasingly directed their attention to the nasal valve area. Indeed, it has been reported that patients with nasal valve collapse are plagued with a greater perception of nasal airway obstruction than those with septal deviation alone.<sup>15</sup> Functional rhinoplasty describes the collection of techniques that surgically addresses airflow by correcting nasal valve disturbances.

In recent years, a number of investigators have attempted to determine the efficacy of functional rhinoplasty techniques in addressing nasal obstruction. Rhee and colleagues<sup>9</sup> performed a 25-year systematic review of the literature searching for evidence supporting the role of functional rhinoplasty and nasal valve repair. He found substantial level IV evidence supporting the efficacy of modern day rhinoplasty techniques for treating nasal obstruction caused by nasal valve collapse.

The literature on functional rhinoplasty lacks randomized control trials, which are usually considered the gold standard and the highest levels of evidence in research. Given the ethical difficulties of blindly randomizing surgical procedures, it is not uncommon to rely on observational and retrospective studies to assess the impact of surgical treatments. Notably, the literature also lacks objective measurement tools to quantify nasal obstruction. Only 27% of the studies found in Rhee's and coworkers review had some type of objective assessment tool. These included validated quality-of-life surveys, such as the one used in the NOSE trial, whereas other studies used rhinomanometry or acoustic rhinometry whose clinical relevance have been questioned previously.<sup>16,17</sup> The NOSE scale, developed by Stewart and colleagues,<sup>6</sup> is one of the main validated evaluation instruments measuring subjective sensation of nasal obstruction and is one of the key accepted measures of postoperative success. Although this scale was initially used to evaluate septoplasty patients, it can be applied to different surgical procedures that address nasal obstruction.

Two studies have separated the effect of nasal valve correction from the septoplasty component. The combined septoplasty and nasal valve approach showed superior improvement in nasal obstruction over septoplasty alone.<sup>12,18</sup> Constantian and Brian<sup>12</sup> showed that internal and external valvular reconstruction increased airflow significantly, but the combination of nasal valve surgery in conjunction with septal surgery increased geometric mean airflow the most by almost five times.

Most<sup>11</sup> conducted a prospective study of 41 patients to measure the efficacy of functional rhinoplasty techniques with the validated NOSE questionnaire. Mean NOSE scores decreased in all patients who underwent functional rhinoplasty. There was a trend toward improved scores in patients who underwent turbinate reduction in conjunction with spreader grafting compared with those subjects who did not undergo these procedures.

The senior author was the principal investigator in the first multicenter, prospective study on quality of life following functional rhinoplasty. Preliminary data of 90 subjects who underwent nasal valve surgery by 12 surgeons across the United States indicate a clear quality-of-life improvement at 3, 6, and 12 months postoperatively as measured by the NOSE questionnaire. It is the hope of the senior author that this investigation and other studies will help to improve the state of third-party reimbursement for techniques used in functional rhinoplasty.

## ANATOMY

The external nasal valve refers to the distal most aperture of the nasal airway. Serving essentially as the nostril orifice, it consists primarily of fibrofatty tissues of the nasal alae in conjunction with the lower lateral cartilages (LLCs), columella, medial crural footplates, the caudal septum, and the piriform aperture.<sup>5,19</sup> The contribution of the external valve to nasal obstruction varies considerably depending on the individual anatomy of the nose (**Fig. 1**).

The internal nasal valve area describes the region of the nasal airway that typically corresponds to the area of greatest resistance to airflow. Pyramidal in shape, it functions as a choke point for nasal airflow and is comprised circumferentially by the caudal aspect of the ULC, the nasal septum, the head of the inferior turbinate, and piriform aperture and nasal floor. The internal valve area is of key importance because it is the critical area of resistance in the anterior nose, affecting nasal airflow by its dynamic regulation of the nasal airway cross-sectional area.<sup>2,5</sup> It is estimated that nasal valve dysfunction exists in approximately 13% of patients with nasal obstruction.<sup>20</sup> The internal nasal valve angle is the narrowest portion of the valve and usually measures 15 to 20 degrees in the leptorrhine nose. The average cross-sectional area of the internal nasal valve area is between 55 and 83 mm<sup>2</sup> (**Fig. 2**). There is some ambiguity in the literature regarding the exact anatomic landmarks that characterize the internal valve area. The previously mentioned description connotes it is a two-dimensional cross section at one point along the nasal airway. In reality, dynamic collapse in this region often occurs at the lateral wall of the nose posterior and caudal to the ULC and superoposterior to the lateral crura. This region between the internal valve area and external nasal valve, sometimes called the “intervalve” area, is typically

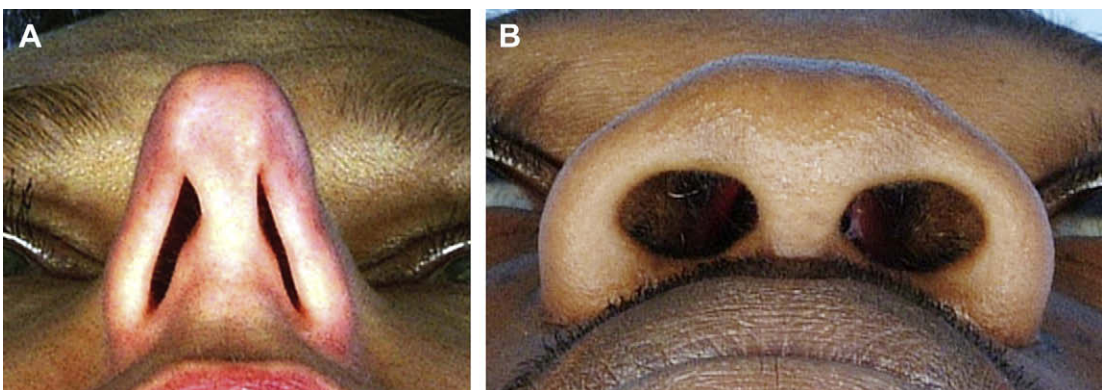
deficient of nasal cartilage. Narrowing or weakness in this area is marked by noses with deep supra-alar creases and inspiratory lateral wall medialization. Narrow, projecting noses with a correspondingly narrow piriform aperture are more likely to demonstrate this abnormality (**Fig. 3**).

The nasal septum is a midline bony and cartilaginous structure that divides the nasal cavity in halves. Posterior and cephalad, the septum is comprised of bone: the perpendicular plate of the ethmoid and the vomer. Along its posterosuperior border, it is attached to the cribriform plate. At its cephalic border, the osseous septum attaches to the frontal bone and its posterior free edge forms the midline partition of the nasal choanae. Anteriorly and caudally, the septum is cartilaginous, formally termed the “quadrangular cartilage.” Firm attachments to osseous structures cephalically (the osseous septum) and ventrally (the maxillary crest) form the basis of its stability. Anteriorly, the maxillary crest terminates at the nasal spine, the osseous attachment of the posterior septal angle of the quadrangular cartilage. Concavities and convexities of the nasal septum can narrow the airway and may compromise laminar airflow.

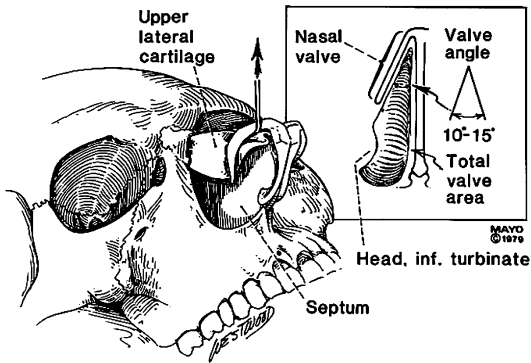
Dorsally and caudally, the cartilaginous septum is interconnected to the ULC and LLC, respectively. Dorsally, the paired, shield-like ULCs are fused in the midline to the dorsal edge of the cartilaginous septum. Caudally, the LLCs have an intimate relationship with the caudal edge of the septum. The inherent stiffness and thickness of the ULC and LLC contribute to the support of the nasal airway against inspiratory collapse.<sup>5,19,21–24</sup>

## PATHOPHYSIOLOGY

The nose serves a multitude of physiologic functions: immunologic, sensory, olfactory, and

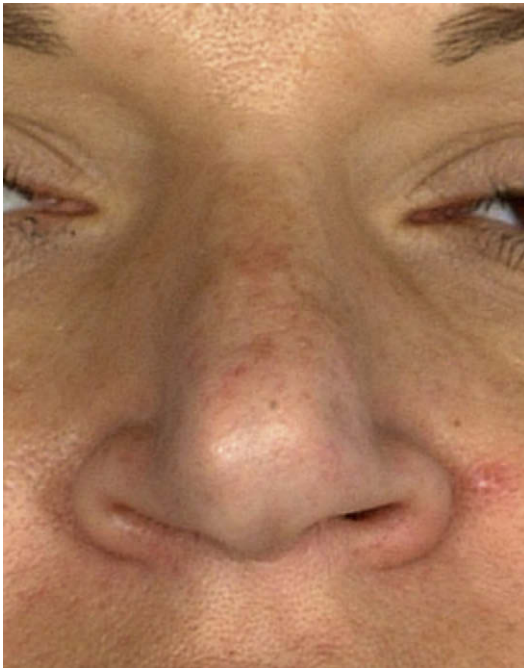


**Fig. 1.** (A) Narrow, projecting nose with external valve insufficiency. (B) Wide, flat nose with broadly patent external valves.



**Fig. 2.** The nasal valve area is bounded by nasal septum. Caudal end of upper lateral cartilage, and soft fibrofatty tissue overlying piriform aperture and floor of nose and posteriorly by the head of the inferior turbinate. This area is shaped like an inverted cone or teardrop, the slitlike apex of which is the nasal valve angle, and normally subtends an angle of 10 to 15 degrees. (From Kasperbauer JL, Kern EB. Nasal valve physiology. *Otolaryngol Clin North Am* 1987;20:792; with permission.)

respiratory. As a respiratory organ it performs a prominent regulatory role. Air enters the nasal cavity, where it is warmed to a temperature of approximately 31°C to 34°C, regardless of outside temperature. It also humidifies the inspired air to



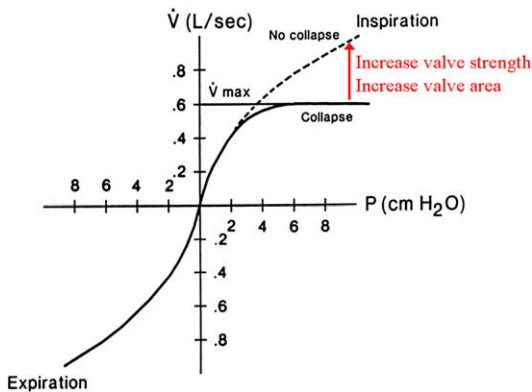
**Fig. 3.** Example of collapse and insufficiency of the lateral wall in the intervalve area. Patient has deep supra-alar creases, concave lateral crura, and inspiratory collapse.

a relative humidity of 90% to 95%.<sup>2</sup> These functions prevent desiccation of the distal airways, which allows optimal gas exchange, and helps maintain temperature homeostasis.

The physiologic role of the nasal valve is not as well defined. With forced inspiration by the nose, collapse of the valve occurs even in patients without nasal valve pathology. It is thought that nasal valve collapse dynamically regulates the cross-sectional area of the nasal cavity preventing the influx of excessive air and ensures proper warming, humidification, and filtration before entering the lungs. The regulation might also assist in olfaction. As the nasal valve narrows, turbulent airflow is created that is redirected toward the olfactory epithelium.<sup>24</sup>

The main factors that contribute to the airflow patterns are the nasal cavity geometry and the flow rate. As inspiration is initiated, airflow is directed in a laminar fashion toward the nasal valve region. This region has the smallest cross-sectional area and causes an acceleration of the flow. Poiseuille's law explains this phenomenon. This principle explains that the volume of a homogeneous fluid (air technically is a fluid) flowing through a tube per unit time (the definition of velocity) is directly proportional to the pressure difference between its ends and the fourth power of its internal radius. It is inversely proportional to the length of the tube and to the viscosity of the fluid. This equation predicts that even small changes in radius greatly affect the flow velocity by increasing it to the fourth power of the radius. Changes in pressure (essentially inspiratory effort) increase velocity, but not to the extent that does a change in radius.<sup>25</sup>

As flow velocity increases through constricted regions of the nasal airway, the Bernoulli theorem then predicts that air pressure decreases. This results in a negative pressure at the point of highest velocity, exerting a collapsing force on the surrounding tube. Whether or not this force leads to actual symptomatic collapse of the nasal airway depends on the magnitude of the force and the strength and geometry of the nasal valve areas. As described, the magnitude of the force depends on the pressure, which is determined by airflow velocity, which is determined by inspiratory effort and nasal airway dimension. The strength of the nasal airway depends on the anatomy of the nose, most notably the width and strength of the lateral nasal wall and the shape and stiffness of the ULC and LLC. The goals of functional rhinoplasty are twofold: to widen the nasal airway aperture and thereby reduce airflow velocity and the negative pressure created within the nose; and to strengthen the valve areas to become more resistant against collapsing pressure forces (Fig. 4).<sup>26,27</sup>



**Fig. 4.** Flow-volume curve demonstrating normal functioning nose (*dotted line*) and nose with valvular collapse (*solid line*). In the pathologic state, at high pressure (inspiratory effort) the nose collapses and no further increase in flow occurs. The goal of surgery is to widen and strengthen the airway in the nasal valve areas, and shift the flow-volume curve from abnormal to normal. (From Kasperbauer JL, Kern FB. Nasal valve physiology. *Otolaryngol Clin North Am* 1987;20:704; with permission.)

## ASSESSMENT

Nasal valve collapse occurs during dynamic inspiration. Examination and assessment of this area is difficult because the soft tissues easily become distorted and stretched with anterior rhinoscopy. In addition, physiologic collapse with deep inspiration can be seen in patients without nasal valve dysfunction. Inspection of the nasal valve without manipulation, such as with flexible nasopharyngoscopy, is valuable. Nasal valve dysfunction can be static, dynamic, or variable. In cases of static dysfunction, narrowing exists that is independent of air flow (eg, septal deviation or turbinate hypertrophy). Dynamic insufficiency is revealed only during active inspiration when poorly supported nasal valve structures collapse.

The Cottle maneuver is performed by placing lateral traction on the cheek to assist in nasal valve opening. The patient is then asked if they feel relief from their nasal obstruction. This assessment has low specificity and is not considered useful.<sup>24</sup> The modified Cottle maneuver is more effective in diagnosis. A fine instrument, such as a cerumen loop, is placed gently within the nares against the lateral nasal wall at the level of maximal observable collapse. The patient is then asked to breathe in through the nose. Collapse is stented by the instrument, which should be held lightly to prevent distortion. This maneuver may predict the potential benefit of surgical nasal valve correction.<sup>28</sup> The procedure should be performed both before and after decongestion to determine the effect of mucosal swelling in symptology.

A variety of objective tests have been used to measure nasal obstruction. Rhinomanometry and acoustic rhinometry are the most favored. A rhinomanometer measures nasal cavity pressure and flow and an acoustic rhinometer measures cross-sectional area and volume within the nasal cavity. Both instruments are used objectively to assess nasal patency. Studies regarding their validity are equivocal. Several articles show no correlation and others show only a moderate relationship between these techniques and a patient's subjective symptoms.<sup>16,29,30</sup> Following the trends in the literature, Kim and colleagues<sup>16</sup> found no significant correlation between rhinomanometry and acoustic rhinometry, and the severity of nasal airway obstruction. Overall, there is a need for a more objective measurement tools to evaluate nasal obstruction.

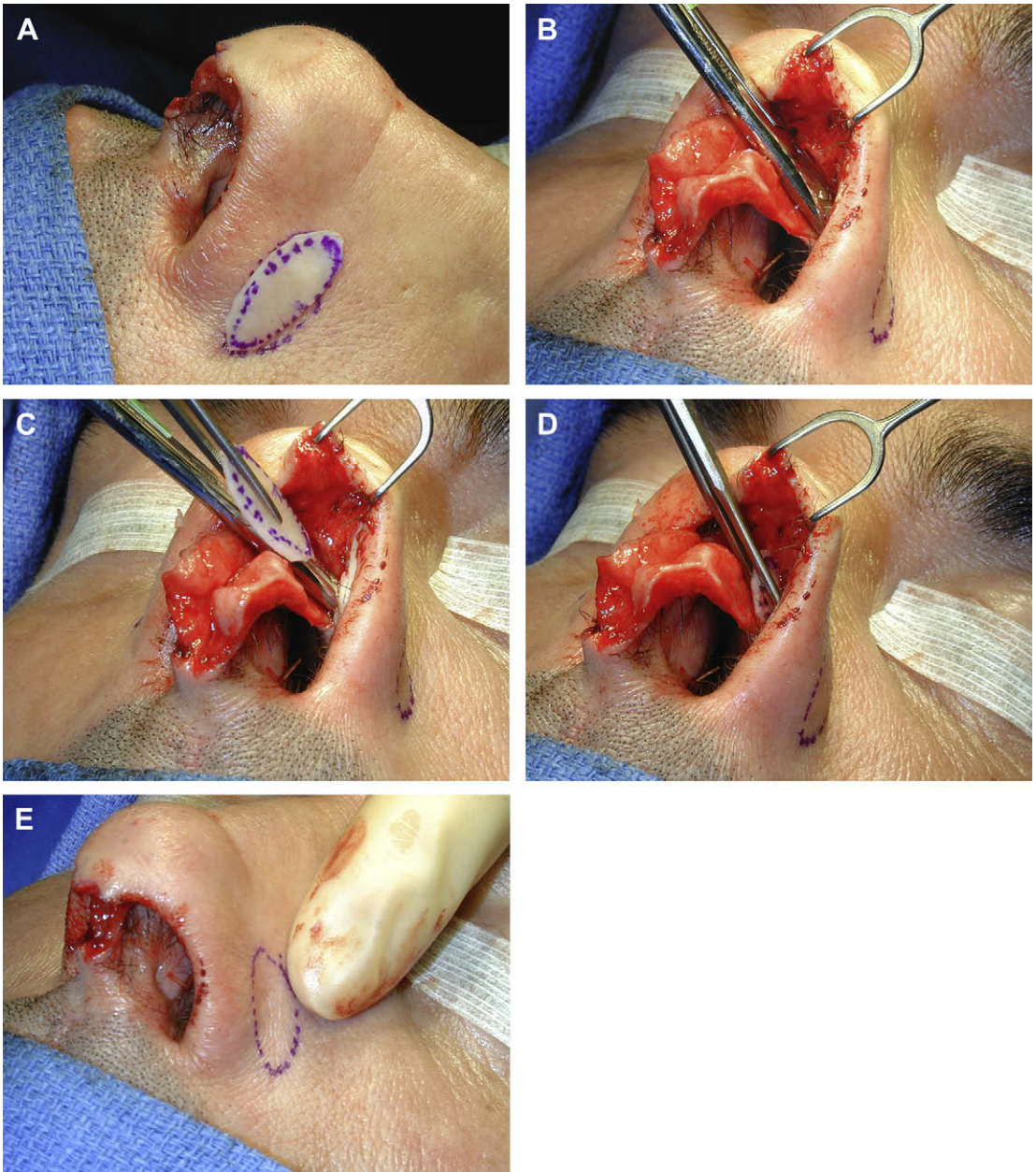
## SURGICAL TECHNIQUES

### *Lateral Wall Insufficiency*

No doubt because of the ambiguous anatomic terminology, the techniques (mostly structural cartilage grafts) used to correct lateral wall problems have not been classified consistently as either internal valve or external valve treatments. Furthermore, the actual locations of these grafts vary according to individual anatomy and pathophysiology; they cannot be consistently labeled as internal or external valve therapies. The authors view such a classification as overly simplistic and one that leads to confusion of a semantic nature. Instead, they view lateral wall reconstruction as a continuum of treatments that span from the internal valve area to the external valve. The graft techniques described in this section are discussed roughly from cephalad to caudal placement (although actual location of any of these grafts may be adjusted according to need).

### *Alar batten grafts*

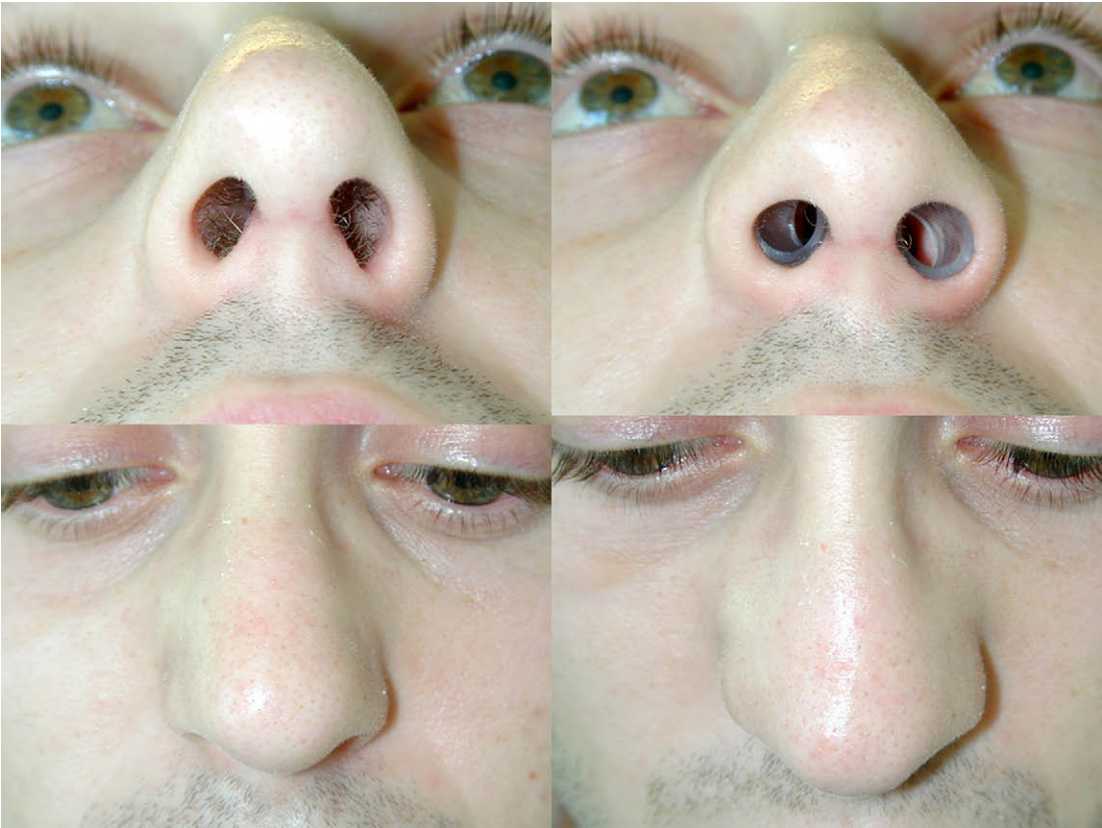
Alar batten grafts are curved cartilaginous supports placed into areas of maximal lateral wall weakness, most typically posterior to the lateral crura. Through the external approach, the grafts are inserted into tight pockets that overlap and extend posterior to the lateral crura. The curvature of the graft is oriented to lateralize the supra-alar area (**Fig. 5**). The lateral aspect of the graft may be caudal to or cephalad to the lateral crura depending on the area of maximal pinching. The grafts may extend beyond the pyriform aperture to add maximal support. In cases in which lateral recurvature of the native lateral crura impinges on the nostril width, the lateral crura may be sutured to the alar batten grafts for lateral stabilization. Internal



**Fig. 5.** Alar batten graft placement through an external rhinoplasty approach. (A) An appropriate-sized graft is carved and placed superficially over the marked optimal position. (B) A precise pocket is dissected from the posterior termination of the lateral crus to a point over the piriform aperture. (C) The graft is placed snugly within the pocket. (D) The graft should extend to or beyond the piriform aperture. (E) After graft placement, palpation confirms correct placement.

vestibular stents may be placed in the postoperative period to prevent postoperative medialization of the lateral wall. These stents may be constructed with pliable plastic stents or sections of nasal-pharyngeal tubes<sup>31</sup> and may be maintained in the nasal vestibules while the patient sleeps for a period of months following surgery (Fig. 6).

The size of the alar batten graft may vary depending on the severity of obstruction to be treated. In general, the longer, wider, and more curved the graft, the greater effect it has on supporting and widening the lateral wall. In some cases, septal cartilage possesses some inherent curvature making it suitable for an alar batten graft.



**Fig. 6.** Splints can be used intranasally to support lateralized healing of alar batten grafts. Cylindric sections of nasopharyngeal tubes may serve as effective splints.

If significant curvature is desired, conchal cartilage may be more suitable. In the most severe of cases, alar batten grafts may be fashioned to be quite long, spanning from the mid-portion of the lateral crus to a point lateral to the lip of the piriform aperture. Such grafts, however, are more likely to create palpable and visible distortion to the external nose.

Through open rhinoplasty, it is important to place the graft within a precise pocket that corresponds to the area of maximal pinching or narrowing as determined preoperatively with the modified Cottle maneuver. Rather than being placed in one consistent anatomic position, the optimal location for alar batten grafts varies from patient to patient. For example, with cephalically malpositioned lateral crura, it is more likely that there is a deficiency of support caudal to the lateral crura. In other cases in which there is poor support of the supra-alar lateral wall, the grafts may be placed cephalad to the lateral crura. The submuscular pocket should be dissected accurately to match the dimensions of the graft so that mobility of the graft is minimized. Should an overly large pocket

be made inadvertently, the graft may be fixated to surrounding tissue with fine absorbable sutures.

An endonasal approach may also be used to place alar batten grafts. In this technique, a marginal incision is made and scissor dissection is executed over the surface of the lateral crura toward the desired pocket for the graft. In most situations this requires that the vector of dissection start superolaterally to establish the plane immediately superficial to the lateral crus, then the dissection redirected in a true lateral (posterior) direction toward the lateral wall and piriform aperture. If this direction change does not occur and the pocket is made too high (cephalad), an unsightly bulge may ensue above the alar crease with no significant improvement in lateral wall support. Once the correct snug pocket is made, the graft may be inserted through the marginal incision into the desired location and orientation.

In some situations, the alar batten graft may cause an undesired contour bulge internally in the nose along the alar sidewall. In some cases, this may lead to exacerbation of the airway obstruction rather than correction. Three scenarios

in which this may occur are discussed. First, the problem may be caused by malposition of the graft such that it slips medial to the lip of the piriform aperture and collapses inward. A short graft or a short dissected pocket may create such a problem. This problem may even happen well after surgery if the patient repeatedly and vigorously manipulates the inside of the nose and lateral wall. Second, a very narrow piriform aperture may predispose to such problems, even if the graft is resting over the lip of the bone. Essentially, the skeletal base of the nose is so narrow that there is not much room for a lateral wall graft. In such cases, it is helpful to use an outwardly curved graft that can compensate for the relatively narrow airway geometry. Third, other techniques that narrow or medialize the domes may pull the lateral termination of the lateral crura medially. This mass effect may lead to inward, medial migration of the lateral crura.

To avoid the aforementioned problems, the surgeon must inspect the lateral wall internally and externally after placement of the grafts and before the completion of surgery. If there is evidence of undesired inward bulging, the graft should be repositioned or modified. Often, a larger or more curved graft can overcome these problems. Alternatively, the alar batten graft may be replaced with an extended lateral crural strut (discussed next). In equivocal cases, the lateral wall and alar batten graft may be supported during the postoperative period with either internal splints or full-thickness lateral wall bolsters, both of which may aid in maintaining optimal graft position. In some cases, patients are advised to use internal stents intermittently over the first 6 to 12 months (period of maximal soft tissue contracture) to promote long-term healing of the grafts in favorable position.

#### **Lateral crural struts and lateral crural grafts**

In most noses, the native lateral crura impart a fair amount of support to the nasal tip and lateral wall. In some noses, however, inherent weakness, cephalic malposition, or iatrogenic injury of the lateral crura leads to reduced support in these areas. This is particularly true when the overall geometry of the nose is projecting, narrow, and thin. Such noses are characterized by narrow piriform apertures, thin alar side walls, and concave alar margins. In these cases, structural reinforcement of the native lateral crura may be indicated. Two types of grafts are commonly used to achieve this end.

The lateral crural strut is an underlay graft placed between the vestibular lining and undersurface of the lateral crus. The lateral crural graft is an overlay graft placed superficial to the lateral crus. In both cases, the grafts can add to the strength and support of weak or compromised native

cartilages. Selection of which graft to use depends on several factors, cosmetic considerations included among them. For example, lateral crural grafts are often used in conjunction with a shield graft to soften the transition from the tip to the alar lobule and lateral wall, improving overall nasal base triangularity. Lateral crural grafts are also favored when the native lateral crura are severely compromised or when elevation of the underlying vestibular skin is risky (eg, scar or atrophy of the lining). In contrast, lateral crural struts have the advantage of being a hidden graft, so that the native cartilage continues to impart the contour through the skin soft tissue envelope (SSTE). This is advantageous in a thin-skinned individual, in whom an onlay graft has a greater chance to transmit an irregularity. Both types of grafts may be used to stiffen and straighten the lateral crura to reinforce a weak lateral wall and to improve triangularity to a misshapen nasal base. Technical details for each type of graft follow.

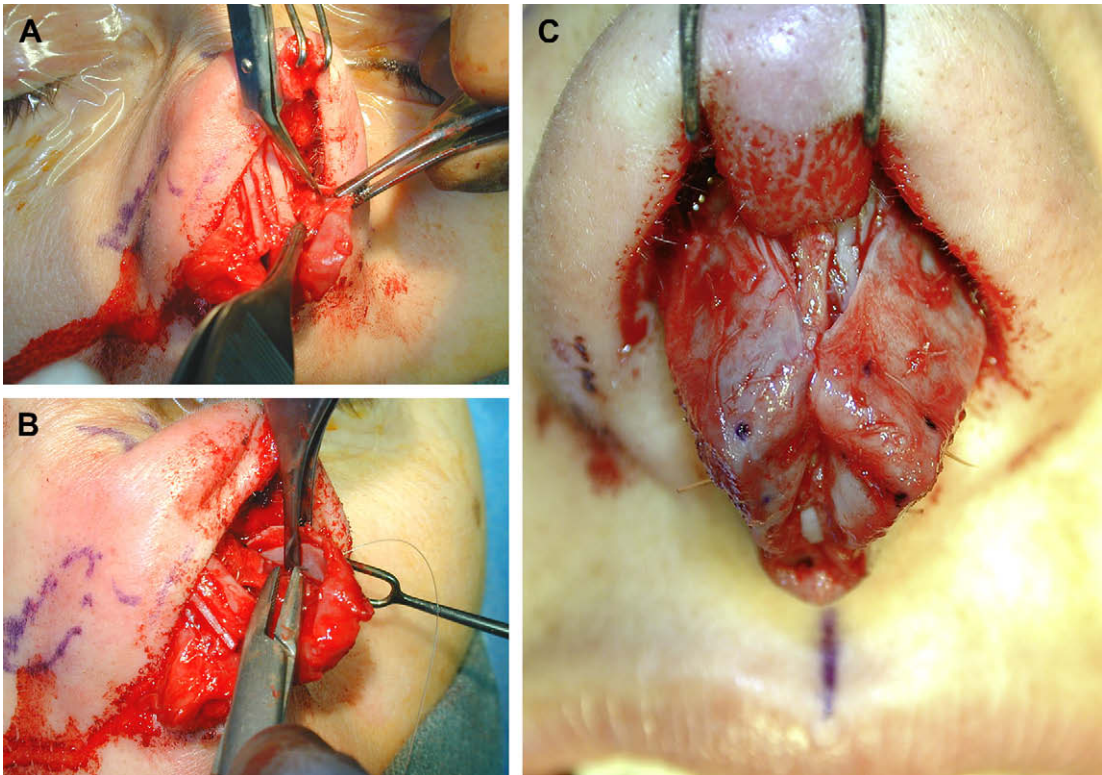
**Lateral crural strut** Lateral crural struts are flat cartilage grafts placed between the undersurface of the lateral crura and the vestibular skin. The vestibular skin should be carefully elevated from the lateral crura from cephalad to caudal. A cephalic trim is generally required to gain access to the free cephalic edge of the lateral crura to execute this dissection. The amount of cartilage removed during the cephalic trim varies depending on the need for volume reduction, but in most cases (because the lateral crural strut technique leads to some flattening of the lateral crura) minimal excision is needed. The caudal attachment of the lateral crus and skin should remain intact to prevent caudal migration of the graft.

Once the epithelium is elevated, the graft should be positioned at the undersurface of the lateral crura to extend from just lateral to the domes to the lateral aspect of the lateral crura or just beyond. The lateral crural strut graft should be secured to the LLC with two to three horizontal mattress 5.0 clear nylon or PDS sutures. The underlying vestibular mucosa should then be apposed to the undersurface of the lateral crural struts with full-thickness chromic suture. Because these grafts need to be thin, straight (or very slightly convex outward), and strong, septal cartilage is ideally suited as a source material. Rib cartilage is also an effective donor source, although the carving of the graft from rib is more difficult (should result in no more than 1 mm thick, but fairly straight graft). Because of its curvature and softness, ear cartilage makes poor material for these grafts. The overall dimensions of the lateral crural strut varies but may range from 2 to 3 cm in length,

6 to 10 mm in width, and about 1 mm in width (Fig. 7).

The lateral crural strut has two main effects. First, it stiffens the lateral crura, allowing it to provide more support to the lateral wall and tip of the nose. Second, it allows for straightening of a convex, concave, or distorted lateral crus. By virtue of the graft's inherent stiffness and shape, the mattress sutures between the lateral crura and the strut graft force the lateral crura into a straighter orientation. This effect may be enhanced when an intradomal suture is combined with the lateral crural graft (a common combination used to refine cosmetically a strong cartilage bulbous tip). In some noses, the lateral crura are fairly straight except for the lateral termination of the cartilage, which recurves inward, much like medial crural footplates may curve laterally. Placing a lateral crural strut that extends just beyond the tail of the lateral crura is an effective way to treat such a problem. From an airway perspective, the stiffening and straightening effects of the lateral crural strut may have a profound impact in adding strength to the lateral wall of the nose, reducing inspiratory collapse.

The extended lateral crural strut with repositioning of the lateral crura is a powerful variation of the strut technique. In this method, the native lateral crura are completely dissected free from the underlying vestibular epithelial bed and left connected to the intermediate crura at the domes. A longer strut graft is sutured to the undersurface of the lateral crus, starting at the desired dome position and extending up to 1.5 cm beyond the termination of the tail of the lateral crus. This extended portion of the lateral crural strut is placed into a precise pocket overhanging the piriform aperture, much like the pocket created for the alar batten graft. The caudal-cephalic position of the pocket depends on desired graft and lateral crural position, but is generally placed quite caudal along the lateral wall. This allows for caudal repositioning of cephalically malpositioned lateral crura. This allows for strengthening of the nose from tip to alar base, making this technique very useful for noses with severe collapse globally along the lateral wall. This technique may also be used to improve triangularity to the tip and base of the nose. Precise and symmetric placement of the pockets and creation of



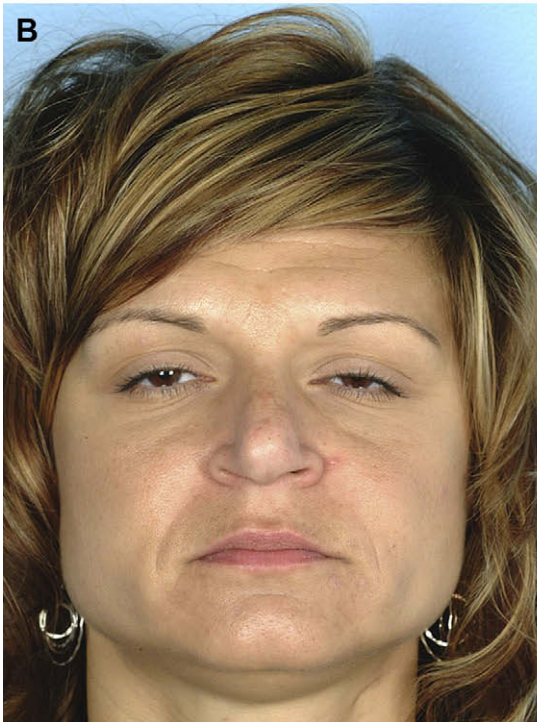
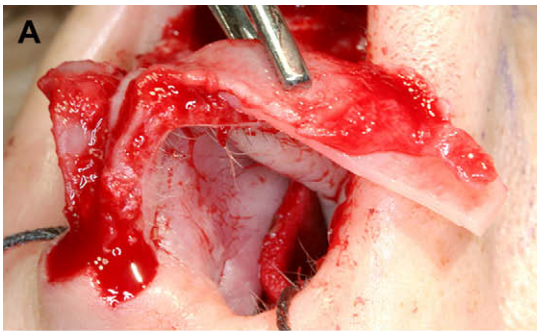
**Fig. 7.** Lateral crural strut placement. (A) The vestibular mucosa is carefully elevated from the undersurface of the lateral crus. (B) The stiff lateral crural strut is sutured to the undersurface of the lateral crus. (C) The lateral crural struts should have the effect of stiffening and straightening the lateral crura. This supports the lateral wall against collapse and can improve triangularity to the base and tip of the nose.

these grafts is critical to create a symmetric nose with appropriate tip position and shape (**Fig. 8**).

Patients who undergo lateral crural struts should understand that there is noticeable contour edge along the internal aspect of the vestibule and lateral wall. This may lead to a slight obstruction of mucous egress in the nose in some patients, but with proper hygiene typically does not lead to a problem.

**Lateral crural graft** Lateral crural grafts may serve many of the same functions as the lateral crural

strut. As discussed previously, these grafts are placed on the superficial surface of the lateral crura instead of the undersurface. Like the lateral crural strut, the lateral crural graft can provide support, stiffening, and straightening of the native lateral crura. The shape, length, and orientation may also be modulated to fit the need of the given patient. The main difficulty with the lateral crural graft is the contribution to external contour. Because it sits superficial to the lateral crura, the graft directly transmits through the skin envelope. This may be acceptable for an individual with thick skin but



**Fig. 8.** An extended lateral crural strut with caudal repositioning of the lateral crura achieves both functional and aesthetic enhancement of the lateral wall and base of the nose. (A) The lateral crus is dissected completely free from the subjacent epithelium and a lateral crural strut, which extends beyond the termination of the lateral crus, is sutured to the undersurface. The extension of the graft is placed into a precise posterolateral pocket. Pre-operative (B, D, F) and postoperative (C, E, G) views of patient who underwent this technique to correct functional and cosmetic problems related to concave, cephalically malpositioned lateral crura.

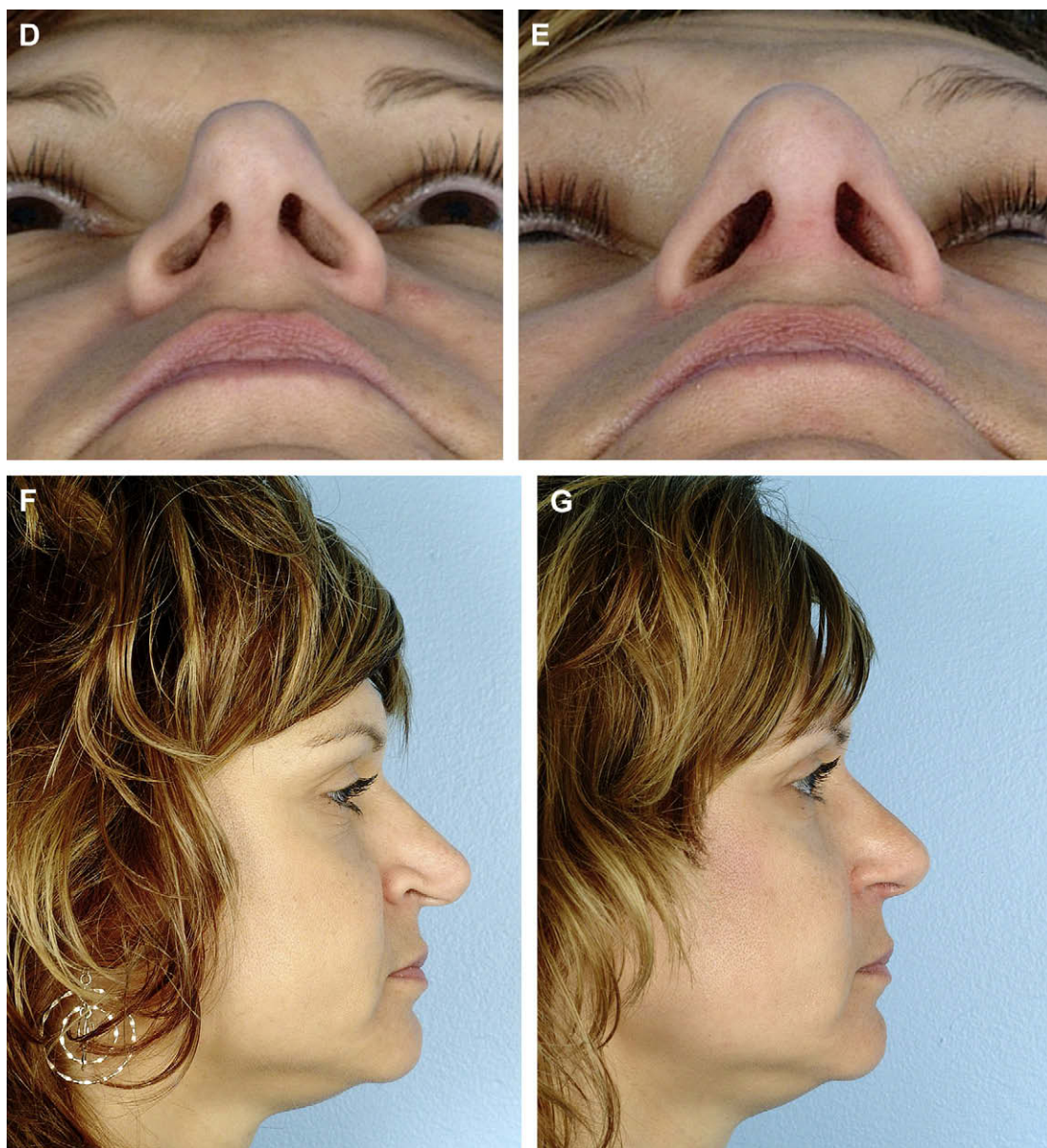
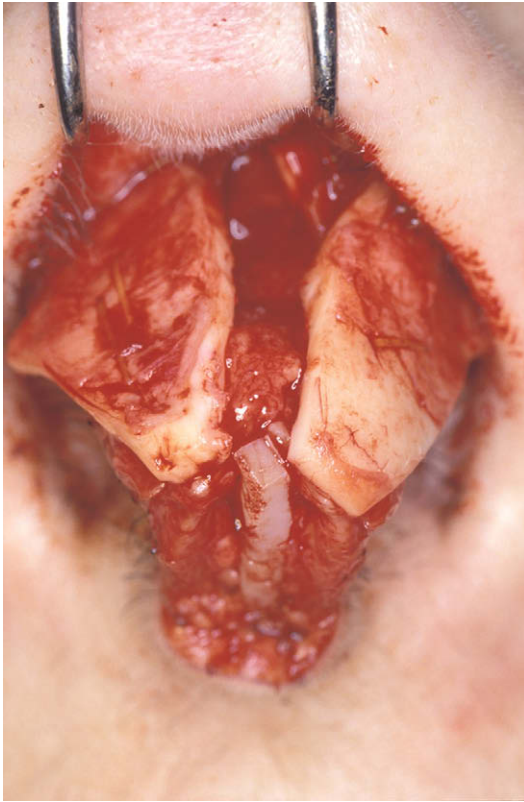
Fig. 8. (continued).

may lead to visible deformities in the thin skin nose.

The lateral crural graft may be useful in revision rhinoplasty when the native lateral crura are missing or are so damaged that they do not provide enough substrate for the lateral crural strut method. In these cases, the grafts may also be termed “lateral crural replacement grafts.” Adequate stiffness, length, and strength of the graft are needed to overcome the lateral wall weakness and collapse in these cases. Precise contouring of the graft with smooth beveled edges is necessary

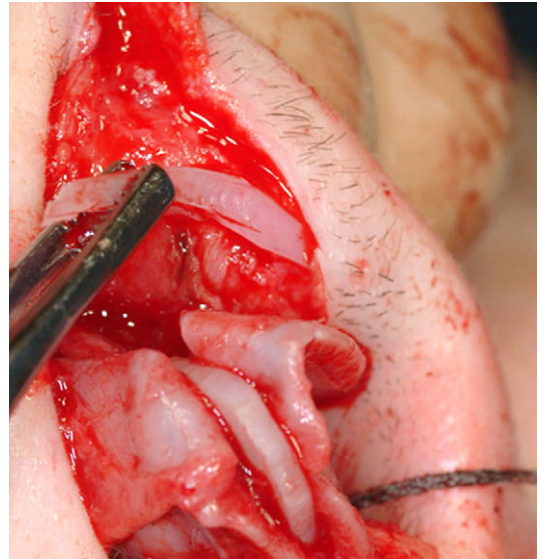
to create appropriate external form. The graft may be suture stabilized medially to whatever LLC remnant is available. Along its length, the graft should be sutured to the underlying scar and soft tissue bed (and cartilage remnants if available). Laterally, the graft may either be secured into a pocket over the piriform aperture or sutured to the dense fibrous deep alar tissue. In some cases, the lateral crural grafts may also be used to support and camouflage the leading anterior edge of a shield tip graft, which extends above the native domes (Fig. 9).



**Fig. 9.** Lateral crural graft to reconstruct severely compromised lateral crura.

#### **Alar rim grafts**

The alar rim graft is a useful technique to provide support along the caudal nostril margin. Because the lateral crura diverge cephalad away from the nostril rim as they extend laterally, there is a deficiency of cartilage support along the nostril margin. This is particularly true in thin, projecting noses and noses with cephalic malposition of the lateral crura. The alar rim graft adds cartilage support in this area of structural deficiency. These long, narrow cartilaginous grafts are placed into precise pockets along the alar rim just caudal to the marginal incision. They measure 1 to 3 mm in thickness and width and 5 to 8 mm in length. The medial aspect of these grafts may be gently bruised to aid in camouflage. They may be stabilized to the surrounding soft tissue or to the lateral aspect of the domal cartilages or a shield graft with a fine absorbable suture. These grafts provide modest support against caudal lateral wall insufficiency. They also improve the concave or pinched appearance of the rim on base view and create a more triangular appearance to the tip and base of the nose (**Fig. 10**).



**Fig. 10.** Alar rim graft being inserted into precise pocket at the alar margin through the marginal incision.

#### **Middle Vault Insufficiency**

In most cases, the middle vault, the ULCs, and the internal valve proper (angle between the ULC and dorsal septum) have less functional airway implications than the lateral wall of the nose. In certain individuals, however, the middle vault can take on greater airway significance. Specifically, noses with a narrow middle vault, a projecting dorsum, or inferomedial collapse of the ULC and inverted-V deformity (typically iatrogenic complications from primary rhinoplasty cartilaginous dorsal reduction) are susceptible to obstruction referable to the middle vault. In particular, patients with short nasal bones and long ULCs are at risk of collapse in this area.

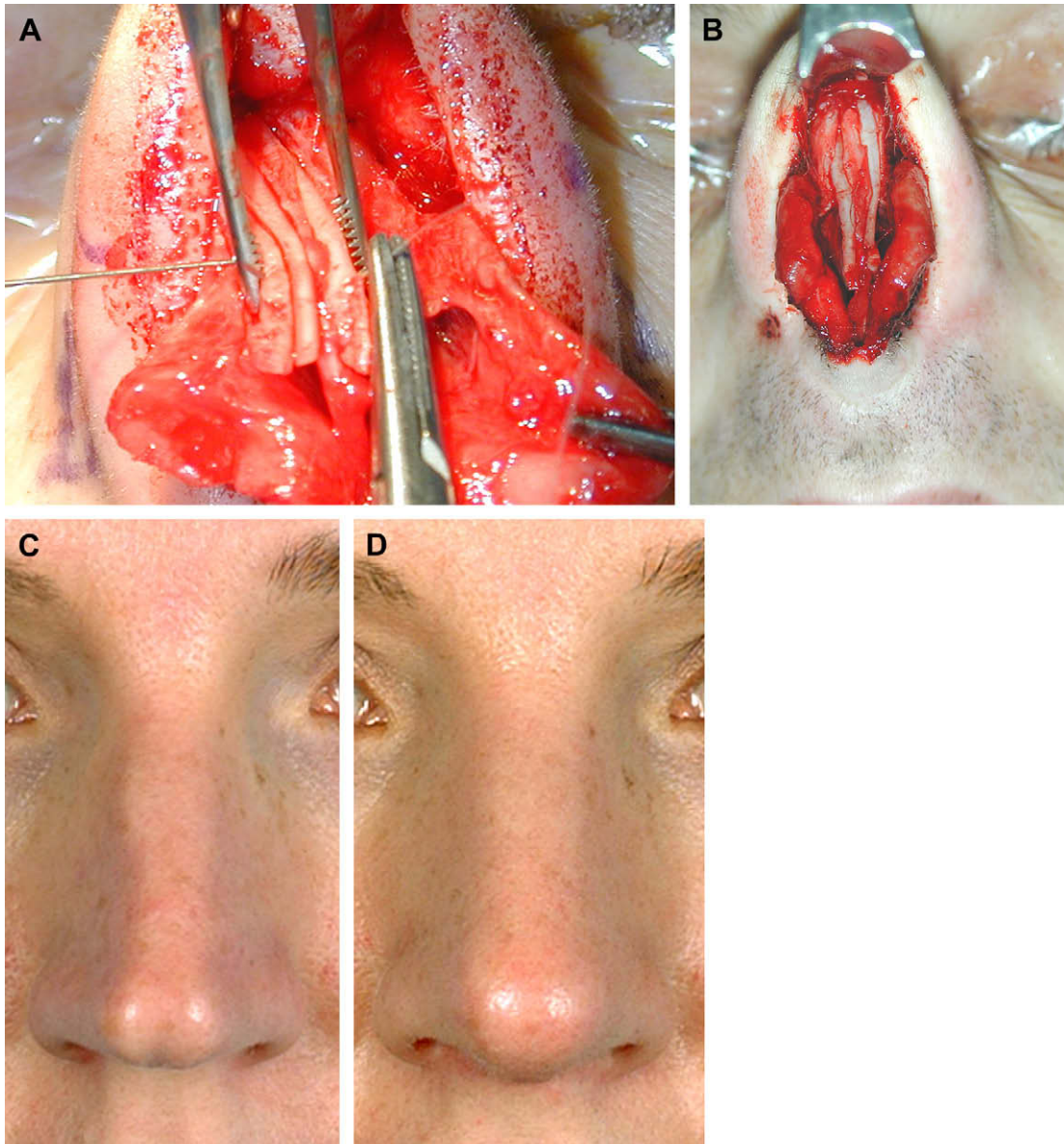
Spreader grafts are long rectangular cartilaginous grafts placed between the dorsal cartilaginous septum and ULC. These grafts are useful to correct functional and cosmetic problems related to a narrow or asymmetric middle vault. These grafts are also used in primary rhinoplasty to prevent ULC collapse in high-risk patients. In particular, when reduction of a cartilaginous dorsal hump leads to excision of the horizontal articulation of the dorsal septum and ULCs, spreader grafts stabilize the middle vault and help restore appropriate horizontal width.

The dimensions of spreader grafts vary depending on specific needs and anatomy, but range from 6 to 12 mm in length, 3 to 5 mm in height, and 2 to 4 mm in thickness. More than one graft may be needed depending on available grafting material

and the deformities. In general, the thicker aspect of the spreader graft is beveled and then positioned cephalad at the rhinion to create the normal appearance of slightly increased width in this area. The grafts may be placed from a dorsal approach after the ULCs are freed from the septum. Mucoperichondrial flaps must first be elevated from the junction of the ULC and septum to prevent injury to the mucosal lining and subsequent cicatrix. Two 5.0 PDS mattress sutures placed through

the ULC, spreaders, and septum should be used for stabilization. The caudal ULC should be pulled caudally during the suture stabilization to straighten any redundancy or curvature. The dorsal profile of the spreader grafts, ULC, and septum should be coplanar and smooth. In situ trimming of the grafts may be needed to ensure an even dorsal surface (**Fig. 11**).

An alternative method of placement of spreader grafts is through a tight subperichondrial tunnel at



**Fig. 11.** Spreader grafts placed through an external rhinoplasty approach. (A) Grafts may be stabilized with a hypodermic needle to facilitate suture placement. (B) Appearance of spreader grafts between the dorsal margin of the septal cartilage and upper lateral cartilages. (C) Preoperative view of patient with pinched middle vault. (D) Postoperative view after spreader grafts.

the junction of the ULC and dorsal septum. In this method, elevation of the septal flaps must not include the dorsal aspect of the quadrilateral cartilage. A mucoperichondrial incision is made high on the septum just caudal to the junction of the ULC and septum. A narrow dissection instrument, such as a Freer elevator, is then used to create a long tight pocket just beneath the dorsal junction between the ULC and septum. Snug placement of a spreader graft into this tunnel cantilevers the ULC away from the dorsal septum, effecting additional widening of the internal nasal valve, as compared with placement of spreaders through an open dorsal approach. In the latter, the ULC is lateralized, but the absolute angle between the septum and ULC does not change. The precise pocket spreader graft creates lateralization and mild flaring of the ULC, leading to increased width and angulation. This effect is achieved because of the bulk of the spreader graft placed below the intact connection between the dorsal margin of the septum and the ULC. This translates to additional airway improvement. This method should be considered in patients with severe obstruction referable to the internal valve. A drawback to this method is the additional width that is incurred. Careful patient selection is required.<sup>32,33</sup>

### ***Brief Comments about Septal Surgery***

The nasal septum represents the most common offending structure causing nasal obstruction. Traditional septal surgery is widely performed and is discussed quite extensively in the literature. Modification of the nasoseptal L strut is less commonly performed, but may be the aspect of the nasal septum creating obstruction. Dorsal deviations may contribute to internal valve area insufficiency and caudal septal deflections may impinge on the external nasal valve. Both dorsal and caudal septal deformities may lead to a crooked nose. Although not reviewed in detail in this manuscript, septal surgery is a critical aspect of the treatment of nasal obstruction in general and nasal valve problems in particular. Because of space limitations the interested reader is referred to other sources detailing the technical aspects of septal surgery.

### **ALTERNATE SURGICAL TECHNIQUES**

Alar batten and spreader grafts have often been referred to as the “workhorses” of functional rhinoplasty surgery. A wide array of techniques has been described in the literature, however, for the correction of nasal valve stenosis or collapse. Most of these alternate methods have not become universally accepted, primarily because they tend

to address only one factor in what is usually a multifactorial problem. In addition, much of the literature supporting these techniques are limited to subjective outcomes measures. Although the techniques previously mentioned are the preferred techniques used by the authors, the following methods may be valuable in certain instances for particular patient problems. A brief description of some notable examples of these techniques follows.

### ***Butterfly Graft***

The butterfly graft is essentially a structurally supportive onlay graft that is placed across the nasal dorsum in the vicinity of the internal valve area. Typically constructed with the entirety of one ear's conchal cartilage, the graft is configured into a symmetric “v” shape with its tip pointing caudally. Essentially, the lateral “wings” of the butterfly graft are pushed downward on the ULCs as they are sutured in place to create outward tension. The cephalic edge of the graft is positioned superior to the caudal edges of the ULCs so that it confers an outward spring effect to widen the middle vault (similar mechanics as flaring sutures). The caudal edge of the graft is deep to the cephalic edge of the ULCs to minimize external contour distortion. The middle vault dorsum can be lowered slightly before placement of the graft to accommodate the thickness of the graft while preserving the pre-existing dorsal height and contour. The graft is then secured with several 5.0 PDS sutures. Clark and Cook<sup>34</sup> studied this technique as it applied to revision rhinoplasty patients, and found that 97% reported complete resolution of their nasal airway obstruction (total N = 72). Eighty-six percent of patients reported an improvement in their cosmetic appearance and those that perceived unsatisfactory cosmetic results stated they would have undergone the surgery again to obtain the nasal patency benefits.

### ***Flaring Sutures***

This technique uses a horizontal mattress suture placed between the two ULCs, using the nasal dorsum as a fulcrum. By means of an open approach to nose the caudal and lateral aspect of the ULC is exposed. A 5.0 clear nylon horizontal mattress stitch is placed in the mid-portion of each ULC, traversing over the cartilaginous bridge of the nose. As the stitch is tightened, the ULCs flare outward, which increases the nasal valve angle. Schlosser and Park<sup>19</sup> described the use of flaring sutures aimed at increasing the internal nasal valve angle in cadaver studies. A total of 34

cadavers underwent this procedure and then acoustic rhinometry and rhinomanometry where used to measure mean cross-sectional area and airway patency. They found that flaring sutures and spreader grafts, in combination, significantly increased cross-sectional area by 18.7%, with a statistically significant increase in nasal patency. Each procedure individually did not significantly increase mean cross-sectional area and spreader grafts showed the least amount of increase overall. Critics of this technique point out that there is likely to be a relaxation of the suture effect on the framework of the nose over time. In addition, there may be risk of a “cheese-string” migration of the suture through the cartilage, causing relaxation of the initial tension created.

### ***Suture Suspension Techniques***

These methods focus on widening the lateral wall of the nose by fixating the lateral crura to lateral anchor point. Menger<sup>35</sup> describes a lateral crural tuck-up technique in which a delivery approach is used to access the lateral aspect of the lateral crura. A drill hole is then made at the piriform aperture and a strong permanent suture is used to fixate the lateral crus to the bony pyramid. As the suture is tightened the lateral crus flares outward in a superolateral direction, widening the angle formed by the lateral nasal wall. Menger described a series of seven patients most of whom reported improved subjective normal nasal breathing and on forced inspiration as compared with before surgery at 3, 6, and 9 months postoperatively. Variations on this technique include using an orbital rim anchor point<sup>36,37</sup> or using a bone anchor suspension technique.<sup>38</sup> Concerns regarding the long-term relaxation of suture-derived tensioning of tissue have been raised regarding these techniques.

### ***Alloplastic Valve Implants***

Mendelson and Golchin<sup>39</sup> described the placement of high-density porous polyethylene implants for the prevention of dynamic collapse. These alloplastic implants, fashioned into the shape of batten grafts, were sutured directly onto the lateral crura in conjunction with suture suspension. The implants were intended to provide structural stabilization and to prevent the sutures from pulling through. In their series, Mendelson and Golchin<sup>39</sup> reviewed 40 patients and found that 92% of them experienced “good” improvement in their nasal airway (subjective patient evaluation). Improvement in nasal airway patency (as measured by physical examination) was statistically significant. Although widening of the lower third of the

nose was noticeable in some cases, cosmetic outcome was satisfactory, with 42% of patients rating their appearance as better than preoperatively and 52% indicating they did not see a difference in their appearance. In recent years, other alloplastic products have become available as an option for lateral wall supportive grafting. To date, there is a lack of long-term data available regarding the safety and efficacy of such implants.

### ***Nasal Valve Dilators***

Multiple devices are available on the market designed to increase nasal valve patency. These products target people with snoring difficulties or athletes. Adhesive external nasal dilator strips are applied to the skin of the nose by gently folding the strip so that it contours the external nasal shape at the level of the nasal valve. Flexible polyester springs exist within the strip, which recoil backward from the bent position. Because the strip is firmly adherent to the skin, the recoil generates a superolateral force on the external nasal valve causing it to open. These devices were found to dilate the nasal airway significantly by reducing resistance, but also helped stiffen the lateral nasal wall preventing inspiratory collapse.<sup>40,41</sup> Roithmann and Chapnik<sup>42</sup> found that 33 patients with nasal obstruction, compared with 51 healthy controls, had significant increase in airway patency with the adhesive nasal strip, as measured by rhinomanometry and acoustic rhinometry. All subjects showed objective measures of increased patency and, except those with mucosal swelling, experienced subjective improvement in sensation of airflow.<sup>42</sup> Racial differences in basic nasal features explain findings that platyrrhine noses often respond paradoxically with an increase in resistance, and overall African Americans seem to have no significant change in nasal resistance when applying nasal valve dilators.<sup>43,44</sup> Another available product is the Nozovent nasal alar dilator. This consists of a semicircle of plastic with flattened free edges. The semicircle is squeezed and introduced into the nasal cavity with the flat free edges lying against nasal vestibule mucosa at the level of the nasal valve. As the plastic ring is released it recoils outward, exerting a lateral force on the internal nasal valve, expanding it. Although it is not as well tolerated, increased nasal patency and decreased resistance similar to (and occasionally better than) the external adhesive strips have been found.<sup>44,45</sup>

### **SUMMARY**

Obstruction at the level of the internal and external nasal valves is often an integral part of severe nasal

obstruction but is frequently overlooked. One must address these areas surgically to improve nasal airflow dynamics maximally and alleviate the patient's perception of obstructed nasal breathing.

## REFERENCES

- Couch ME, Blaugrund J, Kunar D, et al. Physical examination, and the preoperative evaluation. In: Cummings CW, editor. *Otolaryngology head and neck surgery*. Pennsylvania: Mosby; 1998. p. 3–25.
- Behrbohm H. The dual character of nasal surgery. In: Behrbohm H, Tardy ME Jr, editors. *Essentials of septorhinoplasty*. Stuttgart Germany: Thieme; 2004. p. 2–7.
- Toriumi DM, Josen J, Weinberger M, et al. Use of alar batten grafts for correction of nasal valve collapse. *Arch Otolaryngol Head Neck Surg* 1997;123(8):802–8.
- Borges Dinis P, Haider H. Septoplasty: long-term evaluation of results. *Am J Otolaryngol* 2002;23:85–90.
- Haight JSF, Cole P. The site and function of the nasal valve. *Laryngoscope* 1983;93:49–55.
- Stewart MG, Smith TL, Weaver EM, et al. Outcomes after nasal septoplasty: results from the Nasal Obstruction Septoplasty Effectiveness (NOSE) Study. *Am J Otolaryngol* 2004;130:283–90.
- Sedwick JD, Lopez AB, Gajewski BJ, et al. Caudal septoplasty for treatment of septal deviation: aesthetic and functional correction of the nasal base. *Arch Facial Plastic Surg* 2005;7:158–62.
- Most SP. Anterior septal reconstruction: outcomes after a modified extracorporeal septoplasty technique. *Arch Facial Plast Surg* 2006;8:202–7.
- Rhee JS, Arganbright JM, McMullin BT, et al. Evidence supporting functional rhinoplasty or nasal valve repair: a 25-year systematic review. *Otolaryngol Head Neck Surg* 2008;139:10–20.
- Singh A, Patel N, Kenyon G, et al. Is there objective evidence that septal surgery improves nasal airflow? *J Laryngol Otol* 2006;120:916–20.
- Most SP. Analysis of outcomes after functional rhinoplasty using a disease-specific quality of life instrument. *Arch Facial Plast Surg* 2006;8:306–9.
- Constantian MB, Brian CR. The relative importance of septal and nasal valvular surgery in correcting airway obstruction in primary and secondary rhinoplasty. *Plast Reconstr Surg* 1996;98:38–54.
- Jessen M, Ivarsson A, Malm L. Nasal airway resistance and symptoms after functional septoplasty: comparison of findings at 9 months and 9 years. *Clin Otolaryngol Allied Sci* 1989;14:231–4.
- Ho WK, Yuen AP, Tang KC, et al. Time course in the relief of nasal blockage after septal and turbinate surgery: a prospective study. *Arch Otolaryngol Head Neck Surg* 2004;130:324–8.
- Rhee JS, Book DT, Burzynski M, et al. Quality of life assessment in nasal airway obstruction. *Laryngoscope* 2003;113:1118–22.
- Kim CS, Moon BK, Jung DH, et al. Correlation between nasal obstruction symptoms and objective parameters of acoustic rhinometry and rhinomanometry. *Auris Nasus Larynx* 1998;25:45–8.
- Zambetti G, Filiaci F, Romeo R, et al. Assessment of cottle's areas through the application of a mathematical model deriving from acoustic rhinometry and rhinomanometric data. *Clin Otolaryngol* 2005;30:128–34.
- Ricci E, Palonta F, Preti G, et al. Role of nasal valve in the surgically corrected nasal respiratory obstruction: evaluation through rhinomanometry. *Am J Rhinol* 2001;15:307–10.
- Schlosser RJ, Park SS. Surgery for the dysfunctional nasal valve: cadaveric analysis and clinical outcomes. *Arch Facial Plast Surg* 1999;1(2):105–10.
- Elwany S, Thabet H. Obstruction of the nasal valve. *J Laryngol Otol* 1996;100:221–4.
- Ballenger JJ. The clinical anatomy and physiology of the nose and accessory sinuses. In: Ballenger JJ, editor. *Diseases of the nose, throat, and ear*. 12th edition. Philadelphia: Lea & Febiger; 1977. p. 1–22.
- Jafek BW, Dodson BT, et al. Nasal obstruction. In: Bailey BJ, editor. *Head and neck surgery—otolaryngology*. 2nd edition. Philadelphia: Lippincott-Raven; 1998. p. 371–7.
- Tardy ME, Brown RJ. *Surgical anatomy of the nose*. New York: Lippincott-Raven; 1990. p. 1–98.
- Dolan RW. Nasal valve and nasal alar dysfunction. *Facial Plast Surg Clin North Am* 2000;8:447–64.
- Sutera SP, Skalak R. The history of Poiseuille's law. *Annu Rev Fluid Mech* 1993;25:1–19.
- Kelly JT, Prasad AK, Wexler AS. Detailed flow patterns in the nasal cavity. *J Appl Physiol* 2000;89:323–37.
- Wen J, Inthavong K, Tu J, et al. Numerical simulations for the detailed airflow dynamics in a human nasal cavity. *Respir Physiol Neurobiol* 2008;161:125–35.
- Constantinides MS, Adamson PA, Cole P. The long-term effects of open cosmetic septorhinoplasty on nasal air flow. *Arch Otolaryngol Head Neck Surg* 1996;122(1):41–5.
- Warren DW, Hairfield WM, Seaton DL. The relationship between nasal airway cross-sectional area and nasal resistance. *Am J Orthod Dentofac Orthop* 1987;92:390–5.
- Naito K, Cole P, Chaban R, et al. Nasal resistance, sensation of obstruction and rhinoscopic findings compared. *Am J Rhinol* 1988;2:65–9.
- Egan KK, Kim DW. A novel intranasal stent for functional rhinoplasty and nostril stenosis. *Laryngoscope* 2005;115:903–9.
- Fischer H, Gubisch W. Nasal valves—importance and surgical procedures. *Facial Plast Surg* 2006;22:266–80.
- Ballert JA, Park SS. Functional rhinoplasty: treatment of the dysfunctional nasal sidewall. *Plast Surg* 2006;22:49–54.

34. Clark JM, Cook TA. The butterfly graft in functional secondary rhinoplasty. *Laryngoscope* 2002;112:1917–25.
35. Menger DJ. Lateral crus pull-up: a method for collapse of the external nasal valve. *Arch Facial Plast Surg* 2006;8:333–7.
36. Paniello RC. Nasal valve suspension: an effective treatment for nasal valve collapse. *Arch Otolaryngol Head Neck Surg* 1996;122:1342–6.
37. Lee DS, Glasgold AI. Correction of nasal valve stenosis with lateral suture suspension. *Arch Facial Plast Surg* 2001;3:237–40.
38. Friedman M, Ibrahim H, Lee G, et al. A simplified techniques for airway correction at the nasal valve area. *Otol Head Neck Surg* 2004;131:519–24.
39. Mendelson MS, Golchin K. Alar expansion and reinforcement: a new technique to manage nasal valve collapse. *Arch Facial Plast Surg* 2006;8:293–9.
40. Kirkness JP, Wheatley JR, Amis TC. Nasal airflow dynamics: mechanisms and responses associated with an external nasal dilator strip. *Eur Respir J* 2000;15:929–36.
41. Peltonen LI, Vento SI, Simola M, et al. Effects of the nasal strip and dilator on nasal breathing: a study with healthy subjects. *Rhinology* 2004;42:122–5.
42. Roithmann R, Chapnik J. Role of the external nasal dilator in the management of nasal obstruction. *Laryngoscope* 1998;108:712–5.
43. Portugal LG, Mehta RH, Smith BE, et al. Objective assessment of the breathe-right device during exercise in adult males. *Am J Rhinol* 1997;11:393–7.
44. Ellegard E. Mechanical nasal alar dilators. *Rhinol* 2006;44:239–48.
45. Petruson B. Snoring can be reduced when the nasal airflow is increased by the nasal dilator nozovent. *Arch Otol Head Neck Surg* 1990;116:462–4.